

# Growth Factors For Chronic Plantar Fasciitis?

Discussing the potential impact of recent literature in rethinking conventional approaches to recalcitrant plantar fasciitis, these authors explore the use of autologous platelet concentrate injections in treating this common condition.

By Stephen L. Barrett, DPM, CWS, and Susan E. Erredge, DPM, CWS

**P**lantar fasciitis/heel pain syndrome is the most common condition treated by podiatric foot and ankle specialists in the United States.<sup>1</sup> However, the true etiology of plantar fasciitis is still unknown and has been attributed to many different etiological factors. Even the term “plantar fasciitis” is a misnomer as the plantar fascia is really a tendonous aponeurosis and not a fascial layer.<sup>2</sup>

It is entirely possible that our whole paradigm for treating plantar fasciitis is based on a false foundation, especially in light of the histological findings of Lemont, et. al., regarding specimens of resected plantar fascia.<sup>3</sup> Clearly, these authors’ objective histological evidence must make all those who treat plantar fasciitis rethink their concept of the true etiology of plantar fasciitis. Their proposal that the condition we so commonly refer to as plantar fasciitis be called “plantar fasciosis” is valid and more accurately describes the condition.

These findings are further supported by histological analysis of surgical biopsies of tendons which were affected by “tendonitis,” but had no markers of inflammation.<sup>4</sup> An adoption of this correct nomenclature throughout the profession is likely far into the future, but would perhaps orient our understanding of the condition better, which could possibly lead to better treatment modalities and regimens.

It is widely believed that mechanical plantar fasciitis results from

repeated microtrauma due to overuse, which results in microtears of the tissue substance until a macro injury occurs. The physiological process is then initiated via an inflammatory process — an integral part of the wound healing cascade. This injury of the plantar fascia is not dissimilar to any other musculoskeletal pathological process, such as a tendonopathy.<sup>5</sup>

Almekinders and Temple have indicated this may be a too simplistic view that is not accurate in chronic tendon pathology.<sup>6</sup> However, there has been suspicion that mechanical repetitive trauma may not be the true cause of the degenerative process in tendonopathy as previously believed. Some studies have shown the area of tendon most often affected by tendonopathy is not the area of the tendon that is subjected to the highest mechanical force.<sup>7</sup>

## Should We Rethink The Treatment Paradigm For Chronic Plantar Fasciitis?

Does this overwhelming data that recalcitrant plantar fasciitis (fasciosis) is not an inflammatory disorder change our paradigm for treating this condition? These findings cast doubt on two of the mainstays of conservative treatment: non-steroidal anti-inflammatory agents and the corticosteroid injections. A controlled study has demonstrated that an NSAID was no better than a simple analgesic or placebo in the treatment of Achilles tendonopathy.<sup>8</sup> Researchers have also demonstrated that corticosteroid injections do not change the pathological process.<sup>9</sup>

Recently, there has been a push to treat recalcitrant cases of plantar fasciitis with shockwave therapy.<sup>10-13</sup> Results have been mixed, and depending on the cited study, success rates have ranged from 48 percent to 77 percent.<sup>12</sup> The mechanism of this type of therapy is unknown. However, it has been suggested that

extracorporeal shockwave therapy may stimulate or reactivate the healing processes in musculoskeletal tissue. This may be due to micro-destruction of avascular or minimally vascular tissues, which encourage revascularization, the release of local growth factors and the recruitment of appropriate stem cells leading to an enhancement of the intrinsic wound healing process.<sup>14</sup> Drawbacks to this type of treatment include contraindications in patients with neuropathy, destruction of muscle tissue, development of compartment syndromes and cost concerns.<sup>15,16</sup>

The efficacy of ESWT may be based on an enhancement of the wound healing cascade — a conversion of a chronic wound to an acute wound which can then go through a normal physiological wound healing process. This may be similar to the phenomena that has been frequently seen among patients who have had a spontaneous rupture of the plantar fascia after a corticosteroid injection, but eventually have a complete resolution of symptomatology after healing.

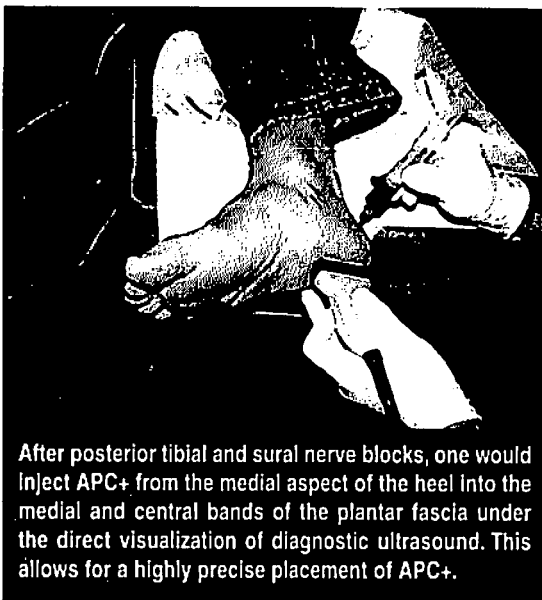
## What The Literature Reveals About Injecting Autologous Platelet Concentrate

Taylor, et. al., demonstrated in rabbit patellar tendons that injecting autologous blood was safe and that the injected tendons were stronger biomechanically than control tendons at 12 weeks.<sup>17</sup> Researchers have documented that autologous platelet concentrate (APC+) has four to six times the normal level of growth factors, which results in fibrocyte migration and induction of neovascular growth.<sup>18</sup> Another group has demonstrated repair of the avascular area of dog menisci with the use of fibrin clots with a morphologically similar tissue to the resected meniscus.<sup>19</sup>

Most importantly, researchers have demonstrated that injecting autologous blood into the origin of the extensor carpi radialis brevis is efficacious in treating recalcitrant lateral epicondylitis (tennis elbow).<sup>20</sup> In their patient series, Edwards, et. al., found 79 percent of their patients were completely relieved of pain — even after strenuous activity — after one injection of autologous blood. Additionally, 89 percent of their patients who required another injection reported complete resolution of



One would pull the yellow platelet poor plasma (as seen above) off the platelet "pellet." Then you would mix the remaining platelets with a small amount of the platelet poor plasma to create the autologous platelet concentrate (APC+).



After posterior tibial and sural nerve blocks, one would inject APC+ from the medial aspect of the heel into the medial and central bands of the plantar fascia under the direct visualization of diagnostic ultrasound. This allows for a highly precise placement of APC+.

symptoms.<sup>21</sup>

The use of autologous platelet rich plasma is not a new treatment.<sup>22</sup> The healing cascade, which is the physiological response to any injury or surgical intervention, is well documented and relies on proteins that are delivered to the healing site by platelets and white blood cells in addition to those proteins that are present in the plasma.<sup>23,24</sup> Successful tissue healing and regeneration requires a scaffold or matrix, undifferentiated cells and signal proteins and adhesion molecules (growth factors). It is well known that platelets affect mitogenic activity of cells like osteoblasts.<sup>25</sup>

Bruder and Haynesworth showed platelets at baseline levels act on human mesenchymal stem cells in cell recruitment.<sup>26</sup> They also determined concentration of platelets above baseline levels has an effect on the attraction of these mesenchymal cells to the surgical site as well as a proliferation of these cells.<sup>27</sup>

We believe injecting APC+ into recalcitrant, symptomatic plantar fascia may cause a reparative effect leading to a resolution of symptoms. We have been utilizing this modality for about a year and a half. We call this technique plantar fasciorrhaphy.

## Taking A Closer Look At Plantar Fasciorrhaphy


In order to gauge the effectiveness of this modality, we enrolled nine patients in an office study. While it is a small patient sample, we believe the study results are promising and may facilitate larger studies in the future.

We selected patients for this technique based on several factors, which included:

- a willingness to participate in an investigational technique;
- a willingness to forgo any other concomitant conservative treatment modality like NSAIDs and orthotic devices; and
- not having had a cortisone injection within 90 days prior to their plantar fasciorrhaphy.

Each individual had a significantly hypoechoic and thickened plantar fascia as demonstrated by diagnostic ultrasound. High-frequency ultrasonography is well documented as a reliable and sensitive method to evaluate human plantar fascia.<sup>28-29</sup>

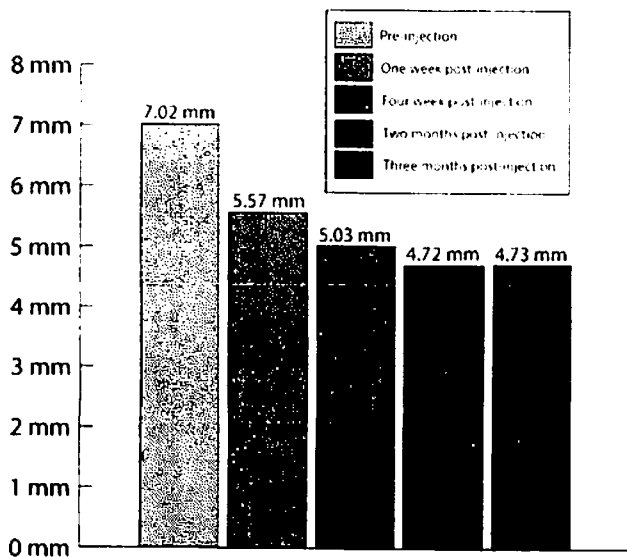
Using the Smart Prep® System (Harvest Technologies), we withdrew 20 cc of each patient's blood. It has been docu-



In these diagnostic ultrasound images, one can see dramatic changes. In the left image, the medial band is 10.3 mm in thickness and is very hypoechoic. The image on the right is only eight days after the injection of APC+. Not only has the thickness decreased to 6.93 mm, there is an improvement in signal intensity.

## What One Small Study Reveals About APC+ Injections

In a nine-patient office study, the authors found that performing an APC+ injection resulted in an average decrease in thickness of the symptomatic medial band as follows:



mented that platelets which are prepared via this system are viable and the same as they were when they were in the patient's bloodstream. The process to harvest the platelets does not damage or change them in any way. After processing, each specimen allowed us to obtain about 3 cc of APC+.

We then anesthetized each patient with a block of the posterior tibial peripheral nerve and sural nerve. We subsequently prepared the foot with a skin antiseptic. Using high-resolution diagnostic ultrasound for guidance, we injected 3 cc of the APC+ into the most hypoechoic areas within the medial and central

bands of the affected fascia with a 25-gauge needle. In order to facilitate the actual placement of the APC+, we needled the affected areas of fascia several times and then achieved the infiltration as the needle was retrograded.

After the procedure, we had the patients wear a below knee cast immobilization boot and instructed them to avoid weightbearing for 48 hours with a subsequent increase in ambulation over the next several days. They were allowed to

return to a comfortable shoe after two days. We monitored patients at one week, two weeks, four weeks, three months, six months and one year. At each visit, we documented subjective assessment with a detailed interview in addition to diagnostic imaging to assess plantar fascial thickness and signal intensity.

## What The Results Of One Small Study Revealed

We used several methods to collect information to determine the efficacy of this technique for treating plantar fasciitis (fasciosis).

First, we took ultrasound measurements of the medial, central and lateral bands prior to the injection of APC+ and obtained post-injection measurements as well for each visit. We also measured the medial, central and lateral bands of the plantar fascia of the asymptomatic foot at each visit for comparison and to serve as a control. The average thickness of the symptomatic medial band prior to injection was 7.02 mm as compared to the average thickness of the asymptomatic medial band, which was 4.88 mm. The average thickness of the central band was 6.59 mm for the symptomatic side versus 4.27 mm for the asymptomatic limb. The average thickness of the lateral band was 4.61 mm for the symptomatic limb versus 3.57 mm for the asymptomatic side.

Post-injection, we noted significant changes not only in thickness but also in the signal intensity of the fascial bands. Prior to injection, the bands of the plantar fascia near the point of origin at the calcaneus appeared thicker and more hypoechoic as compared to the asymptomatic side. One can see this in the hard copy images captured at pre-injection.

The post-injection measurements we obtained at one week, four weeks, two months and three months reveal a significant change in thickness as well as signal intensity. At one week post-injection, the medial band showed an average reduction in thickness of 1.45 mm. By four weeks, the average reduction in thickness was 1.99 mm. At two months, it was 2.30 mm. At three months, it was 2.29 mm. The central band also decreased in thickness. There

was little change in the lateral band but note these patients demonstrated the typical type of plantar fascial pain, which is located more medially at the medial tubercle than laterally. At the end of three months, the average thickness of the previously symptomatic medial and central bands was 5.03 mm and 5.39 mm respectively. The average thickness of the asymptomatic medial and central bands was 4.63 mm and 4.20 mm respectively.

Nine patients were enrolled in this study. Six patients achieved complete resolution of symptoms after two months. One patient had complete resolution of pain after being dropped from the study due to an injection of a corticosteroid. One of the remaining two patients had complete resolution after a second injection of APC+, and the last patient had only occasional pain when walking barefoot. Interestingly, all patients in this study had improvement that was noted on diagnostic ultrasound.

At one year, seven of nine patients had complete resolution of their plantar fascial pain for a 77.8 percent success rate, which is very comparable to the results from the lateral epicondylitis study.<sup>20</sup> One patient was considered a failure and the final patient had all pain resolved, but was dismissed from the study because of a subsequent steroid injection.

## Final Thoughts

The advent of new diagnostic technology in addition to the recent histological findings documented in the current literature casts serious doubt upon our current understanding of the true etiological nature and subsequent treatment of plantar fasciitis (fasciosis). Our successful early findings with injecting APC+ indicate this may become a very commonly used modality in treating this difficult condition.

Certainly, the injection of autologous blood is safe and none of our patients experienced any complications from their plantar fasciiorraphy. This technique cannot impair the biomechanical function of the foot, unlike other invasive procedures that transect or resect part or the entire human plantar fascia.

While these early results are encouraging, the overall efficacy of injecting APC+ into human plantar fascia for treating recalcitrant plantar fasciitis is likely to be greater when combined with a complete, multi-factorial treatment regimen versus a single, isolated modality as we used in this study. ■

*Dr. Barrett is a Fellow of the American College of Foot and Ankle Surgeons, and an Associate Professor within the Arizona Podiatric Medicine Program at Midwestern University College of Health Sciences in Glendale, Ariz. He is a consultant and speaker for Harvest Technologies, Inc.*

*Dr. Erredge practices at Dolly Vinsant Memorial Hospital in San Benito, Texas.*

## References

1. APMA News Release, <http://www.apma.org/nr041101.htm>, April 11, 2001
2. Gibbon W and Long G: Ultrasound of the plantar aponeurosis (fascia). *Skeletal Radiology* 28:21-26, 1999.
3. Lemont H, Ammirati M, Usen N: Plantar Fasciitis—a degenerative process (fasciosis) without inflammation. *JAPMA* 93(3): 234-237, 2003.
4. Fukuda H, Hamada K, Yamanaka: Pathology and pathogenesis of bursal side

- rotator cuff tears viewed from en bloc histologic sections. *Clin Orthop* 254:75-80, 1990.
5. Jozsa L, Reffy A, Kannus P: Pathological alterations in human tendons. *Arch Orthop Trauma Surg* 110:25-31 1990.
6. Almekinders LC, Temple JD: Etiology, diagnosis and treatment of tendonitis: an analysis of the literature. *Med Sci Sports Exerc* 30:1183-1190.
7. Bey JB, Kwon Song H, Wehrli F, Soslowky LJ: Intratendinous strain fields of the intact supraspinatus tendon: the effect of glenohumeral joint position and tendon region. *J Orthop Res* 20:869-874.
8. Astrom M, Westlin N: No effect of piroxicam on Achilles tendonopathy: a randomized study of 70 patients. *Acta Orthop Scand* 63:631-634 1992.
9. Price R, Sinclair M, Heinrich I, Gibson T: Local injection treatment of tennis elbow: Hydrocortisone, triamcinolone and lignocaine compared. *Br J Rheumatol* 30:39-44 1991.
10. Alvarez R: Preliminary results on the safety and efficacy of the Ossatron for treatment of plantar fasciitis. *Foot Ankle Int* 23(3):197-203, 2002.
11. Rompe J, Hopf C, Nafe B, Burger R: Low energy extracorporeal shock wave therapy for painful heel: a prospective controlled single blind study. *Arch Orthop Trauma Surg* 115:75-79.
12. Hammer D, Rupp S, Kreutz A, et al: Extracorporeal shockwave therapy (ESWT) in patients with chronic proximal plantar fasciitis. *Foot Ankle Int* 23(4):309-313, 2002.
13. Wang C, Chen H, Huang T: Shockwave therapy for patients with plantar fasciitis: a one year follow-up study. *Foot Ankle Int* 23(3):204-207, 2002.
14. Theil M: Application of shockwaves in medicine. *Clin Orthop* 387:18-21, 2001.
15. FDA Talk Paper, FDA Approves Shockwave device for severe heel pain. <http://www.fda.gov/bbs/topics/ANSWERS/ANS01045.html>.
16. Durst H, Blatter G, Kusteer M: Case Report—Osteonecrosis of the humeral head after extracorporeal shockwave lithotripsy. *JBJS (Br)* 84B:744-746, 2002.
17. Taylor M, Norman T, Clovis N, et al: The response of rabbit patellar tendons after autologous blood injection. *Med Sci Sports Exerc* 34(1):70-73, 2002.
18. Kevy S, Jacobsen M, Benoit P: The biology of platelet concentrate as prepared by the Harvest Technologies SmartPrep system. Presented at the 3rd Annual Techvest Conference on Tissue Repair, Replacement, and Regeneration. New York, NY, October 23, 2001.
19. Arnoczky SP, Warren RF, Spivak JM: Meniscal repair using an exogenous fibrin clot. *JBJS* 70A (8):1209-1217, 1988.
20. Edwards S, Calandruccio J: Autologous blood injections for refractory lateral epicondylitis. *J Hand Surg* 28A (2):272-278, 2003.
21. Cohen I, Diegelman R, Yager D, et al: Wound Care and Wound Healing, in Principles of Surgery, ed by I Seymore, S Schwartz, T Shires, F Spencer, A Galloway, pp. 263-296, New York, 1999.
22. Marx R, Carlson E, Eichstaedt R, et al: Platelet-rich plasma: growth factor enhancement for bone and grafts. *Oral Surgery, Oral Medicine, Oral Pathology* 85(6):643-646, 1998.
23. Kirsner R, Eaglestein W: The Wound healing process. *Derm Clinics* 11(4):629-640, 1993.
24. Gruber P, Varga F, Fischer M, et al: Platelets stimulate proliferation of bone cells: involvement of platelet-derived growth factor, microparticles, and membranes. *Clin Oral Impl Res* 13:529-535, 2002.
25. Miyazono F, Okabe T, Urabe A, et al: A platelet factor that stimulates the proliferation of vascular endothelial cells. *Biochem Biophys Res Commun* 126: 83-88, 1985.
26. Cardinal E, Chhem R, Beauregard C, Aubin B, Pelletier M: Plantar fasciitis: sonographic evaluation. *Radiology* 201:257-259, 1996.
27. Kane D, Greaney T, Shanahan, et al: The role of ultrasonography in the diagnosis and management of idiopathic plantar fasciitis. *Rheumatology* 40:1002-1008, 2001.
28. Vohra P, Kincaid B, Japom C, et al: Ultrasonographic evaluation of plantar fascial bands—a retrospective study of 211 symptomatic feet. *JAPMA* 92(8):444-449, 2002.
29. Wall J, Harkness M, Crawford A: Ultrasound diagnosis of plantar fasciitis. *Foot Ankle Int* 14:465-470, 1993.